



Short Communication

Successful therapy for protein-losing enteropathy caused by chronic neuronopathic Gaucher disease



A.A. Mhanni^{a,b}, M. Kozenko^c, J.N. Hartley^b, M. Deneau^d, W. El-Matary^a, C. Rockman-Greenberg^{a,b,*}

^a Department of Pediatrics and Child Health, University of Manitoba, Canada

^b Department of Biochemistry and Medical Genetics, University of Manitoba, Canada

^c Department of Pediatrics, McMaster University, Canada

^d Department of Pediatrics, University of Utah, Canada

ARTICLE INFO

Article history:

Received 13 October 2015

Received in revised form 1 December 2015

Accepted 1 December 2015

Available online xxxx

ABSTRACT

Gaucher disease (OMIM #230800) is caused by β -glucosidase deficiency and primarily involves the mononuclear phagocyte system (also called Reticuloendothelial System or Macrophage System). The disease is classified into three main phenotypes based on the presence or absence of neurological manifestations: non-neuronopathic (type 1), acute neuronopathic (type 2) and chronic neuronopathic (type 3). Typical manifestations include hepatosplenomegaly, skeletal deformities, hematological abnormalities, interstitial lung fibrosis and neurodegeneration in neuronopathic cases. Mesenteric lymphadenopathy with resultant protein losing enteropathy (PLE) has only been rarely described. Mesenteric lymphadenopathy may lead to intestinal lymphatic obstruction and secondary lymphangiectasia resulting in chronic diarrhea, abdominal pain and weight loss. Fecal protein loss with secondary hypoalbuminemia can be significant. We report a male with Chronic Neuronopathic Gaucher disease (GD) (homozygous for c.1448T>C (NM_000157.3) *GBA* mutation) who at 16 years of age developed intractable abdominal pain, diarrhea and weight loss. This was caused by PLE secondary to intestinal lymphangiectasia caused by calcified mesenteric lymphadenopathy despite prior long term enzyme replacement therapy (ERT) and/or substrate reduction therapy (SRT). His older similarly affected sister who had been receiving treatment with ERT and/or SRT remains stable on these treatments with no evidence of mesenteric lymphadenopathy. Medical management with total parenteral nutrition, daily medium chain triglyceride-oil (MCT) supplementation, low dose oral budesonide, continued oral SRT and an increased dose of parenteral ERT has stabilized his condition with resolution of the gastrointestinal symptoms and appropriate weight gain.

© 2015 The Authors. Published by Elsevier Inc. This is an open access article under the CC BY-NC-ND license (<http://creativecommons.org/licenses/by-nc-nd/4.0/>).

1. Clinical report

We report the unusual complication of calcified mesenteric lymphadenopathy and PLE in a 16 year old male with chronic neuronopathic GD. He presented at 14 months of age with gross hepatosplenomegaly and pancytopenia and was diagnosed as having chronic neuronopathic GD which was known to affect his older sister. The diagnosis was established on clinical presentation, decreased enzyme activity, homozygosity for the c.1448T>C (NM_000157.3) *GBA* mutation and the confirmed diagnosis in his older sister. The parents are first cousins of Canadian Aboriginal ancestry and the family history is otherwise noncontributory. At 17 months of age, he was started on bi-weekly intravenous infusions of mannose-terminated recombinant glucocerebrosidase (imiglucerase, Genzyme, a Sanofi Company, Cambridge, MA) (100 units/kg) (ERT). He continued on ERT for 10 years until

miglustat as substrate reduction therapy (SRT) was introduced at 10 years and 6 months of age; a decision determined by evidence of progression of interstitial lung disease and neurologic involvement along with difficulties with central line access and recurrent line sepsis. The dose of miglustat was increased over an 8 week period to 400 mg/day and imiglucerase infusions were tapered over a 5 month period. He continued on miglustat oral monotherapy for 12 months. Due to significant increase in his biomarkers (chitotriosidase and ACE), worsening of hematologic parameters (low platelet count and hemoglobin) and increased volume of solid organs (liver and spleen), imiglucerase (30 μ /kg) every three weeks was reintroduced in conjunction with miglustat (400 mg per day). Detailed description of his treatment course follows below.

2. Response to imiglucerase monotherapy

Organ volume, biomarker levels and hematologic parameters responded favorably and remained stable over the course of 10 years of ERT alone. The presence of bone marrow infiltration on femur and

* Corresponding author at: FE229-820 Sherbrook Street, Winnipeg MB R3A 1R9, Canada.

E-mail address: cgreenberg@hsc.mb.ca (C. Rockman-Greenberg).

tibial MRI was noted two years after initiation of Cerezyme therapy. The presence of avascular necrosis of the right femoral head was noted after 10 years of therapy. The presence of increasing interstitial pulmonary markings on CT scan of the chest was first noted 6 years after initiation of therapy with progression noted in the yearly subsequent studies. Clinically this was associated with a history of chronic cough and wheezes; however his spirometry assessments remained normal. His neurological examination 3 years after initiation of therapy recorded mild deficit in coordination but no other abnormalities noted. After 10 years of therapy, his neurological examination showed mild intention tremors and wide based gait. Vertical saccades were normal. His horizontal saccades were slow with blink saccade synkinesis. There was slight superior pulsion with horizontal saccades. Smooth pursuit was within normal limits. There was no primary position or gaze evoked nystagmus. The vestibulo-ocular reflex was normal.

Brainstem Auditory Response was normal prior to the start of therapy but this showed the presence of bilateral auditory neuropathy after 10 years of therapy. On formal developmental assessment at 33 months of age (16 months of therapy) his developmental quotient was 80. A follow-up assessment at 6 years of age (55 months of therapy) his developmental quotient was 75. Ongoing psychometric assessments identified the presence of a decline in his overall intellectual functioning within the low to borderline range.

3. Response to miglustat monotherapy

Monotherapy treatment with miglustat was begun after 10 years of imiglucerase in parallel with weaning from the ERT. This was well tolerated with good compliance on a lactose-restricted diet. After a year of miglustat therapy alone his neurologic examination showed absence of saccades, intention tremors in the hands and persistent concerns about mild incoordination. Chest CT scan revealed stability of interstitial lung markings. Bone MRI showed stability with no interval changes in bone appearance. Cognitive function improvement was documented and academically he performed at his grade-appropriate level. Disease progression however was noted through documented increase in hepatosplenomegaly, increasing biomarkers and deterioration of hematologic parameters. Combination therapy was then reinitiated.

4. Response to combination therapy (imiglucerase and miglustat)

On a dose of miglustat of 400 mg per day and imiglucerase intravenous infusions every 3 weeks (30 μ /kg) his biomarkers' response, hematologic parameters and organ volume all showed considerable improvement and stability over the subsequent year. His bone MRI also showed stabilization and sustained improvement with no evidence of progression of his avascular necrosis of the right femoral epiphysis.

Chest CT scan monitoring demonstrated reduction of interlobular septal thickening and the centrilobular interstitium of the lungs.

5. The development of mesenteric lymphadenopathy

At age 16 years, after 15 years of ERT treatment and 4 years of combined ERT/SRT treatment, he presented with a 3 week history of more than 10 watery bowel movements day and night and abdominal pain. This was preceded by a 4 month history of intermittent diarrhea and the patient's weight dropped from the 25th percentile to <3rd percentile over the course of 5 months. The patient's stool tested positive for fat globules and his 72 hour fat excretion study confirmed that fat excretion was elevated. The fecal pH was 8 and his stools were never positive for reducing substances. Fecal 24 hour alpha-1-antitrypsin level was elevated at 292 mg/dL ($N < 54$), with a normal serum alpha-1-antitrypsin level, consistent with PLE. Further evidence for PLE included persistent lymphopenia over the 6 months prior to the diagnosis with lymphocyte counts less than 10% of the normal total white blood cell count. Blood smear was normal. There was also hypogammaglobulinemia with his IgG level of 3.47 g/L ($N 6.9-16.2$). Serum albumin at presentation was 14 g/L ($N 33-49$). There were no opportunistic infections detected in blood or stool and stool cultures for bacteria, viruses and parasites were consistently negative. Monospot test was negative. CRP was negative. Serum calcium, phosphate, parathyroid hormone and 25 hydroxy vitamin D were all normal and vitamin supplementation was not prescribed. Plain abdomen radiographs showed thickened intestinal walls and calcified mesenteric lymph nodes (Fig. 1-A). Abdominal ultrasound did not demonstrate any significant ascites. A barium swallow with small bowel follow through revealed diffusely thickened bowel with thumb-printing from ligament of Treitz to the terminal ileum consistent with intestinal lymphangiectasia. Conventional upper gastrointestinal endoscopy with biopsies was normal as the disease was distal to the biopsy site. A diagnosis of PLE secondary to intestinal lymphangiectasia caused by calcified mesenteric lymphadenopathy was made. Video capsule endoscopy was offered to the patient but was declined. The patient followed a low fat diet supplemented with 30 ml of MCT oil 3 times a day, along with 9 mg daily of oral budesonide and total parenteral nutrition (TPN) overnight 6 nights a week. On this regime, the patient's diarrhea subsided, he became free of any abdominal pain, his weight increased by 15 kg to the 50th percentile, his serum albumin normalized, he now attends school regularly, socializes with friends and his school performance has improved. This has been sustained now for 3 years. The dose of the intravenous ERT was increased to 100 μ /kg and the oral SRT was continued at the same dose of 400 mg/day. Plain abdomen X-rays obtained at baseline (Fig. 1-A) and 34 months (Fig. 1-B) after initiation of therapy demonstrated less numerous and less dense lymph nodes than previously seen. Other disease manifestations remain stable. His sister who has also been treated

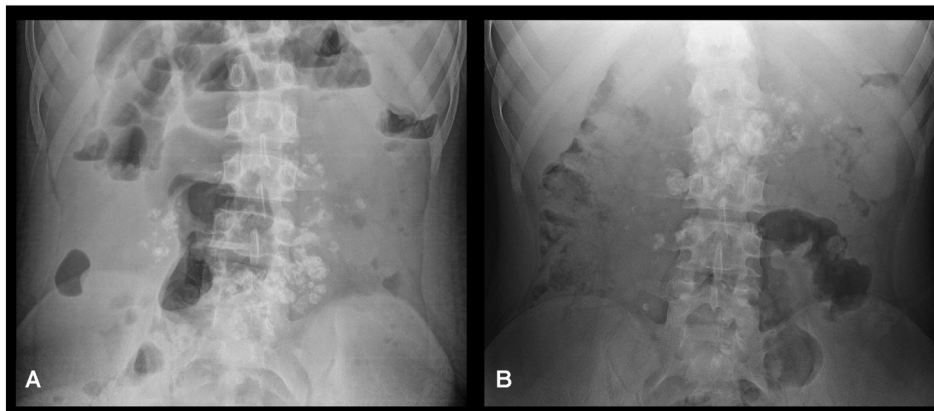


Fig. 1. (A) Plain abdomen X-ray showing multiple calcified mesenteric lymph nodes. (B) 34 month follow-up plain film showing fewer and less dense calcified mesenteric lymph nodes.

with combination ERT and SRT (due to disease progression and failure of monotherapy with ERT or SRT) remains stable with no evidence clinically for PLE and no evidence for mesenteric lymphadenopathy.

6. Discussion

Fourteen patients with GD and mesenteric lymphadenopathy have been reported in the literature [5–10]. All were pediatric patients and mesenteric lymphadenopathy developed despite ERT. The chronic neuropathic phenotype was documented in 8 of the 14 reported patients. Mutations were documented in 10 patients; 9 had p.L444P homozygosity and 1 was homozygous for the R359Q mutation. The mesenteric lymphadenopathy was progressive with subsequent severe PLE and major comorbidities in 3 of the reported cases with mesenteric lymphadenopathy [5,9,10]. The lack of development of PLE in our patient's sister nor in 11 of the reported patients highlights the intrafamilial variability and non-predictability of the development and expression of this complication.

Combined ERT and SRT has been reported to be associated with improvement of neurological manifestations in patients with chronic neuropathic GD [1,3] and halt the progression of pulmonary [2] and skeletal [4] involvement. In our patient, SRT was introduced at 10 years of age due to evidence of progression of interstitial lung disease and neurologic involvement along with difficulties with central line access. On combined ERT and SRT stability of the neurologic manifestations, interstitial lung disease and skeletal involvement was noted along with continued response of the hematologic parameters, organ volume and biomarker stability. However after 15 years of ERT treatment and 4 years of combined ERT/SRT treatment the patient developed severe PLE due to intestinal lymphangiectasia with calcified mesenteric lymphadenopathy. The precise age at onset of the mesenteric lymphadenopathy is uncertain as regular abdominal X-rays were not performed over the years. The presence of mesenteric calcification however suggests that they have been present possibly for years. The mechanisms underlying mesenteric lymphadenopathy are unclear. It is possible that lymph nodes are poorly permeable to the ERT and SRT. Furthermore the development of fibrous tissues in the lymph nodes reduces drug access to this tissue. Recently Burrows et al., 2015, reported mesenteric lymph node histology in a patient with mesenteric lymphadenopathy and PLE where the lymphoid architecture was significantly replaced with an acellular material with areas of calcification [11].

There is no known effective treatment for calcified mesenteric lymphadenopathy in GD. In all reported cases, the mesenteric lymphadenopathy did not improve with ERT or with combined ERT and SRT therapy, as in our patient and did not prevent the development of this complication.

The plain abdomen x-ray obtained 34 months after initiation of therapy appeared to demonstrate less numerous and less dense lymph nodes. This coincided with the patient's clinical improvement suggesting that further progression of PLE may be halted and mesenteric lymph node calcification may be reversed with optimization of ERT and SRT along with aggressive supportive treatment even in clinically advanced disease. Since there are no premonitory signs to predict the occurrence of PLE, we recommend close follow-up of all patients with GD when mesenteric lymphadenopathy becomes evident with timely treatment with TPN, MCT supplements and steroids as earlier detection may allow for timely intervention and perhaps prevention of severe PLE. This report highlights the emerging long-term complications of GD reflecting progression of disease burden despite long-term treatment with ERT and SRT.

Compliance with ethics guidelines

A. A. Mhanni, M. Kozenko, J. N. Hartley, M. Deneau, W. El-Matary and C. Rockman-Greenberg declare that they have no conflict of interest.

Informed consent

All procedures followed were in accordance with the ethical standards of the responsible committee on human experimentation (institutional and national) and with the Helsinki Declaration of 1975, as revised in 2000 [5]. Informed consent was obtained from the patient (and his family) reported in this manuscript and the patient agrees with the content and with submitting this paper for consideration for publication in Molecular Genetics and Metabolism. We did not require Research Ethics Board approval from the University of Manitoba as the medications reported in this manuscript are all approved and funded medications in Canada.

Details of the contributions of individual authors

A. A. Mhanni, M. Kozenko, and C. Rockman- Greenberg were involved in the development of the clinical treatment protocols of enzyme replacement therapy and substrate reduction therapy. M Deneau and W. El-Matery were primarily responsible for the development of the treatment protocol of the protein-losing enteropathy. A.A. Mhanni and C. Rockman-Greenberg were the primary authors who developed the content of the manuscript but all authors critically reviewed the manuscript and offered suggestions regarding the content.

Acknowledgments

We thank Erika Bloomfield for administrative assistance.

References

- [1] Capablo, et al., Neurologic improvement in a type 3 Gaucher disease patient treated with imiglucerase/miglustat combination, *Epilepsia* 48 (2007) 1406–1408.
- [2] Schiffman, et al., Randomized controlled trial of miglustat in Gaucher disease type 3, *Ann. Neurol.* 64 (2008) 514–522.
- [3] Cox-Brinkman, et al., Potential efficacy of enzyme replacement and substrate reduction therapy in three siblings with Gaucher disease type III, *J. Inher. Metab. Dis.* 31 (2008) 745–752.
- [4] Pastores, et al., Goal-oriented therapy with miglustat in Gaucher disease, *Curr. Med. Res. Opin.* 25 (2009) 23–37.
- [5] T.A. Burrow, M.B. Cohen, R. Bokulic, G. Deutsch, A. Choudhary, R.A. Falcone Jr., G.A. Grabowski, Gaucher disease: progressive mesenteric and mediastinal lymphadenopathy despite enzyme therapy, *J. Pediatr.* 150 (2007) 202–206.
- [6] D.J. Fowler, M.A. Weber, G. Anderson, M. Malone, N.J. Sebire, A. Vellodi, Ultrastructural features of Gaucher disease treated with enzyme replacement therapy presenting as mesenteric mass lesions, *Fetal Pediatr. Pathol.* 25 (2006) 241–248.
- [7] A.K. Lim, A. Vellodi, K. McHugh, Mesenteric mass in a young girl—an unusual site for Gaucher's disease, *Pediatr. Radiol.* 32 (2002) 674–676.
- [8] B. Yagci, O. Salor, B. Yalcin, F. Gurakan, S. Gucer, M. Buyukpamukcu, Giant lymphadenopathy infiltrated by Gaucher cells mimicking lymphoma, *Pediatr. Blood Cancer* 52 (2009) 870–871.
- [9] B.H. Lee, D.-Y. Kim, G.-H. Kim, K.-J. Cho, H.-K. Yoon, H.-W. Yoo, Progressive mesenteric lymphadenopathy with protein-losing enteropathy; a devastating complication in Gaucher disease, *Mol. Genet. Metab.* 105 (2012) 522–524.
- [10] M. Abdelwahab, H. SeifEldien, Mesenteric and mediastinal lymphadenopathy in Egyptian children with Gaucher disease types 1 and 3 treated with enzyme replacement therapy, *J. Pediatr. Hematol. Oncol.* 37 (5) (July, 2015) e316–e322.
- [11] T.A. Burrow, Y. Sun, C.E. Prada, L. Bailey, W. Zhang, A. Brewer, S.W. Wu, K.D.R. Setchell, D. Witte, M.B. Cohen, G.A. Grabowski, CNS, lung, and lymph node involvement in Gaucher disease type 3 after 11 years of therapy: clinical, histopathologic, and biochemical findings, *Mol. Genet. Metab.* 114 (2015) 233–241.